

UDC 617.761-009.24:616.832.94.005.1

DOI <https://doi.org/10.32782/2226-2008-2024-5-8>

D. I. Hnatovska <https://orcid.org/0009-0008-7346-446X>
Yu. O. Solodovnikova <https://orcid.org/0000-0002-2544-9766>
A. S. Son <https://orcid.org/0000-0002-3239-7992>

FEATURES OF OCULOMOTOR DISORDERS IN THE RUPTURE OF CEREBRAL ARTERIAL ANEURYSMS

Odesa National Medical University, Odesa, Ukraine

UDC 617.761-009.24:616.832.94.005.1

D. I. Hnatovska, Yu. O. Solodovnikova, A. S. Son**FEATURES OF OCULOMOTOR DISORDERS IN THE RUPTURE OF CEREBRAL ARTERIAL ANEURYSMS***Odesa National Medical University, Odesa, Ukraine*

Introduction. It is known that subarachnoid hemorrhages (SAH) resulting from the rupture of arterial aneurysms (AAs) can cause vision disorders, which is a significant factor in disability among the working population.

The aim of the study is to investigate the features of oculomotor disorders in patients with SAH due to AA rupture.

Materials and methods. The study involved 472 medical reports of patients in the acute period of AAs rupture. The mean age was 52 years, with 54.4% of patients being female and 45.6% male. Clinical-neurological and radiological methods, as well as statistical analysis were used in the study.

Results. The presence of oculomotor disorders in aneurysmal subarachnoid hemorrhage is associated with a better treatment outcome, but it decreases the probability of discharge without neurological deficit ($p < 0.001$). The rupture localization significantly affects its occurrence: internal carotid artery (ICA) ruptures (33.3%) notably increase risk ($OR = 3.2$) compared to the anterior communicating artery (ACA) ruptures (29.5%) ($p = 0.003$). Localization of AA rupture also influences the outcomes. In Group 1 the basilar artery (BA) ruptures (4.3%) correlate with mild neurological deficits, while in Group 2, ICA (33.3%) ruptures favor outcomes without deficits, unlike other regions, on example MCA (21.8%) and ACA (29.5%) ($p < 0.001$).

Conclusions. The presence of oculomotor disorders in aneurysmal SAH correlates with better treatment outcomes, but decreases the probability of discharge without neurological deficit. Rupture localization significantly impacts oculomotor disorder likelihood, with ICA aneurysms showing increased risk compared to ACA aneurysms. In terms of recovery, localization of the rupture is also significant: in Group 1 BA ruptures correlate with mild neurological deficits, while in Group 2, ICA ruptures favor outcomes without deficits, unlike other regions, for example middle cerebral artery (MCA) and ACA.

Key words: oculomotor disorders; subarachnoid haemorrhage; arterial aneurysms.

УДК 617.761-009.24:616.832.94.005.1

Д. І. Гнатівська, Ю. О. Солодовнікова, А. С. Сон**ОСОБЛИВОСТІ ОКОРУХОВИХ РОЗЛАДІВ ПРИ РОЗРИВІ ЦЕРЕБРАЛЬНИХ АРТЕРІАЛЬНИХ АНЕВРИЗМ***Одеський національний медичний університет, Одеса, Україна*

Стаття присвячена дослідженню особливостей окорухових розладів (ОР) у пацієнтів з розривом артеріальних аневризм (АА) різних локалізацій. Проведено ретроспективне когортне дослідження 472 історій хвороби пацієнтів в гострому періоді розриву АА. Було вивчено вплив локалізації розриву АА на вірогідність виникнення ОР і результат лікування, а також зв'язок ОР з результатами лікування. Виявлено, що наявність ОР збільшує вірогідність задовільного результату лікування, але знижує вірогідність виписки без неврологічного дефіциту ($p < 0.001$). При розриві АА внутрішньої сонної артерії (ВСА) шанси на виникнення ОР вищі у 3.2 рази порівняно з розривами АА передньої мозкової артерії ($p = 0.003$). Відсутність ОР при розривах АА базиллярної артерії підвищує ймовірність виписки з легким неврологічним дефіцитом, а наявність при розривах АА ВСА підвищує ймовірність виписки без дефіциту, тоді як розриви АА середньої та передньої мозкових артерій збільшують ризик значного дефіциту ($p < 0.001$).

Ключові слова: окорухові розлади, субарахноїдальний крововилив, артеріальні аневризми.

Introduction. It is known that subarachnoid hemorrhage (SAH) resulting from the rupture of arterial aneurysms (AAs) can cause oculomotor disorders (OMDs), which are a significant factor in the disability of the working-age population.

Previous studies confirm that paresis or paralysis of the oculomotor nerves can be a useful clinical indicator for diagnosing the enlargement of intracranial aneurysms [1, 2]. The rupture of AAs may cause isolated abducens nerve

paresis, which is considered a sign of a posterior inferior cerebellar artery aneurysm [3], and isolated oculomotor nerve paralysis [4, 5], which typically occurs with AAs of other localizations, such as the posterior communicating artery (PCA) segment [6] of the internal carotid artery (ICA) [7], due to their anatomical proximity [8], the basilar artery (BA), the posterior cerebral artery, and the superior cerebellar artery [9]. However, there were cases of its occurrence in anterior communicating artery (ACA) aneurysm ruptures [8].

The severity of paresis usually depends on the direction and localization of the aneurysm, as well as the rate of expansion of its sac, and to a lesser extent, on the volume of

© D. I. Hnatovska, Yu. O. Solodovnikova, A. S. Son, 2024

Стаття поширюється на умовах ліцензії



blood in the subarachnoid space. It is known that the PCA segment of the ICA is the most common site of aneurysms associated with the development of ipsilateral oculomotor nerve paresis. The prevalence of such cases accounts for 34–56% of all aneurysm ruptures in this area [10].

The results of a 2024 study described that the presence of oculomotor nerve paralysis in SAH patients was associated with better treatment outcomes [2].

It is also known that the rupture of AAs can cause bilateral abducens nerve paresis. A similar case was described in Tokyo after the rupture of an ACA aneurysm, where computed tomographic angiography diagnosed a 15-mm ACA aneurysm in a patient with SAH. The aneurysm was successfully clipped, after which the bilateral abducens nerve paresis gradually regressed [11].

The aim of the study is to investigate the features of oculomotor disorders in patients with SAH caused by AA rupture.

Materials and methods. The present study is a retrospective cohort analysis. It included 472 medical records of patients in the acute phase of SAH due to AA rupture who received inpatient treatment from 2000 to 2023 at the Municipal Clinical Hospital No. 11 of the Odesa City Council. Among them 54.4% were female, and 45.6% were male.

Based on the presence of oculomotor disorders, patients with aneurysmal SAH were divided into two groups. Group 1 included patients without oculomotor disorders – 394 (84%) patients, of which 206 (52.3%) patients were female and 188 (47.7%) were male. Group 2 included patients with oculomotor disorders – 78 (16%) patients, of which 50 (64.1%) patients were female and 28 (35.9%) were male. Inclusion criteria were: SAH within a period of up to 21 days, SAH resulting from the AA rupture, patient age of 18 years or older. Exclusion criteria were: SAH beyond 21 days, other causes of SAH (e.g., traumatic, arteriovenous malformation etc.), patient age under 18 years. Patients were categorized based on the presence or absence of OMDs, including isolated or combined involvement of the oculomotor, trochlear, or abducens nerves. Group 1 consisted of patients with SAH resulting from AA rupture in the acute phase without OMDs, while Group 2 consisted of patients with SAH resulting from AA rupture in the acute phase with OMDs. Due to the distribution characteristics of the hemorrhage and the severe condition of patients with aneurysmal SAH, differentiating isolated and combined oculomotor nerve damage can be significantly challenging. However, the cumulative clinical contribution of oculomotor impairments to the prognosis of SAH outcomes due to AA rupture is extremely important.

The research methods included the analysis of clinical data of patients, specifically data from neurological examinations and radiological data, which comprised computed tomography (CT) and computed tomographic angiography. Statistical analysis methods were also applied, including descriptive statistics for the treatment of SAH patients due to AA rupture with and without oculomotor disorders, binary logistic regression to compare the likelihood of oculomotor disorders in different AA localizations, and multinomial logistic regression to assess the relationship between the presence of oculomotor

impairments, AA rupture localization, and treatment outcomes.

Patient distribution by aneurysm localization in both groups followed the aneurysm localization classification by M. G. Yaşargil, which is based on an anatomical analysis of the segmental arrangement of brain arterial aneurysms [12].

Treatment outcomes were evaluated based on the presence and severity of neurological deficits and the need for external care at discharge. Treatment results were classified as: “no neurological deficit”, “mild deficit, does not require assistance”, “severe deficit, requires assistance or vegetative state”, “death”, and “transferred to another hospital”. Calculations were performed using Jamovi software, version 2.3.28.0, with results considered statistically significant at $p < 0.05$.

The study was conducted in compliance with the principles of the Ethical Code of the World Medical Association (Helsinki Declaration). Ethical approval for the study was obtained under Protocol No. 7 of the Ethics Committee of Odesa National Medical University dated September 30, 2019.

Results. Analysis of the localization of ruptured aneurysms revealed that in Group 1, the primary cause of hemorrhage was the rupture of aneurysms in ACA (51%), whereas in Group 2, the most common causes were aneurysms of ICA (33.3%) and ACA (29.5%) (Fig. 1).

Using binary logistic regression to compare the likelihood of developing OMDs at different AA rupture localizations, it was found that patients with AA ruptures in the ICA region had 3.2 times higher odds of developing OMDs compared to those with ACA aneurysms ($OR=3.2$; $CI=1.2-5.2$; $p=0.003$).

In contrast, AA ruptures in the ACA region were associated with a significantly lower risk of OMDs compared to ruptures in the vertebral artery (VA) region ($OR=0.21$; $CI=0.017-0.437$; $p=0.0048$) (Fig. 2).

A multinomial logistic regression analysis for Group 1 patients showed that BA, ICA, ACA, and middle cerebral artery (MCA) aneurysm ruptures significantly increased the likelihood of discharge with mild neurological deficits. At the same time, there was a lower probability of both discharge with no neurological deficit and discharge with poor treatment outcomes or death ($p < 0.001$).

In all cases, the localization of a ruptured aneurysm in the MCA region demonstrated the highest likelihood of severe neurological deficits compared to VA ruptures and increased the likelihood of mild neurological deficits compared to other aneurysm rupture localizations. Additionally, ACA ruptures decreased the likelihood of mild neurological deficits ($p < 0.001$).

In Group 2, for patients with oculomotor disorders, VA aneurysm ruptures significantly reduced the likelihood of discharge without neurological deficits or with mild neurological deficits ($p < 0.001$). ICA aneurysm ruptures increased the likelihood of discharge without neurological deficits ($OR=2.65e-7$; $CI=5.53e-8-1.27e-6$; $p < 0.001$). Conversely, MCA and ICA ruptures increased the likelihood of discharge with severe neurological deficits rather than mild deficits compared to BA aneurysm ruptures ($OR=1.01e+7$; $CI=3.05e+6-3.36e+7$; $p < 0.001$).

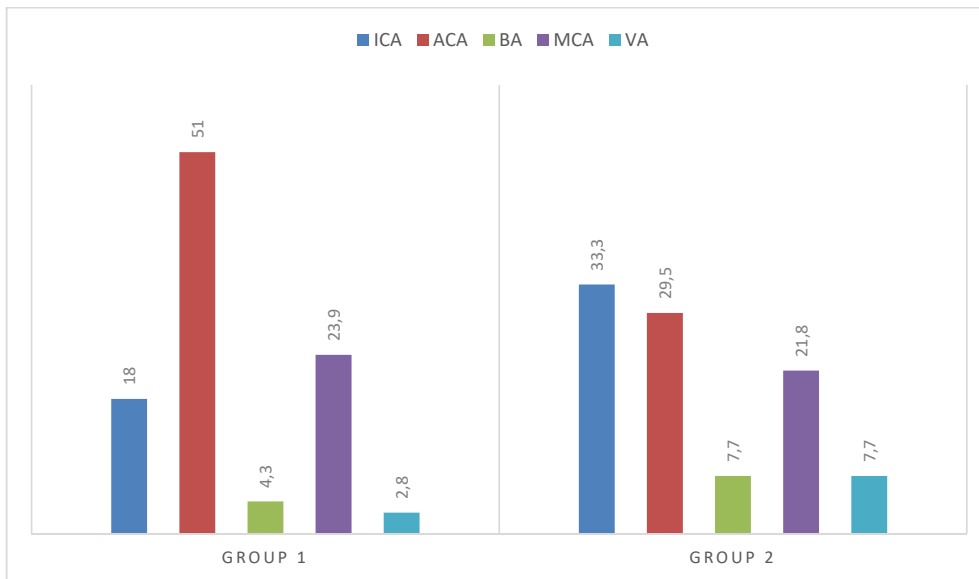


Fig. 1. Distribution by aneurysm location between groups

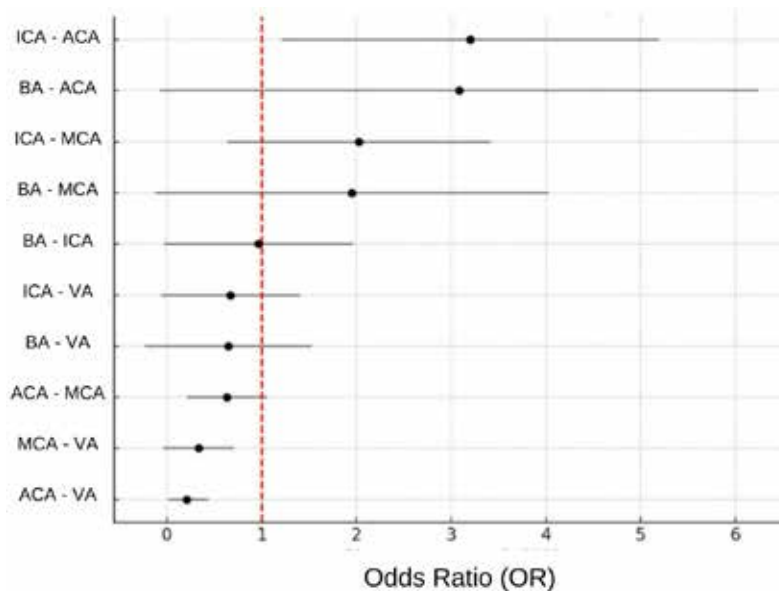


Fig. 2. Result of binomial logistic regression

Furthermore, BA aneurysm ruptures also increased the likelihood of death compared to discharge with severe neurological deficits when compared to ICA ruptures (OR=0.00336; CI=0.00336-0.00336; p<0.001). VA aneurysm ruptures reduced the likelihood of death compared to ACA ruptures (OR=0.99; CI=0.3104-65.23; p<0.001).

As a result, the localization of AA ruptures significantly affects treatment outcomes. The absence of oculomotor disorders in BA, ICA, ACA, and MCA aneurysm ruptures, compared to VA aneurysm ruptures, reliably increases the likelihood of discharge with mild neurological deficits and reduces the risk of severe neurological deficits, vegetative states, or death. MCA ruptures present the highest risk of discharge with severe neurological deficits, while ACA and ICA ruptures slightly increase the likelihood of death compared to ruptures in other regions.

The presence of oculomotor disorders in ICA ruptures increases the chances of discharge without neurological deficits, whereas ACA, VA, and MCA ruptures increase the likelihood of discharge with mild neurological deficits compared to BA ruptures. MCA and ACA ruptures are associated with a higher risk of discharge with severe neurological deficits, while ACA ruptures also increase the risk of death compared to other aneurysm rupture localizations (Fig. 3, 4, 5, 6).

In studying the impact of OMDs on treatment outcomes, we found that the presence of OMDs was associated with worse treatment outcomes. In Group 1 (patients without OMDs), the most frequent treatment outcome was “no neurological deficit” (42.9%), while in Group 2 (patients with OMDs), the most common outcome was “severe deficit, requires assistance, or vegetative state” (32.1%) (Fig. 7).

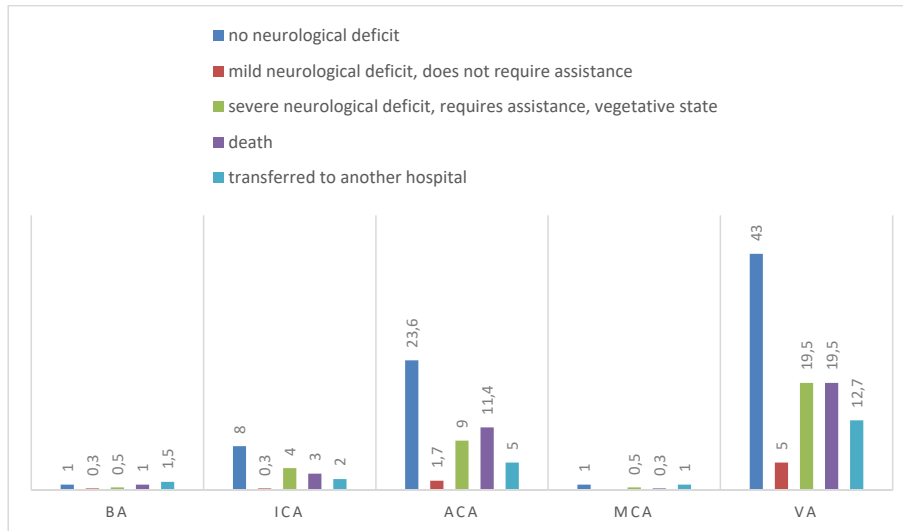


Fig. 3. Frequency distribution of treatment outcome depending on AA localization in Group 1 ($\chi^2=29.3$; $df=16$; $p<0.022$)

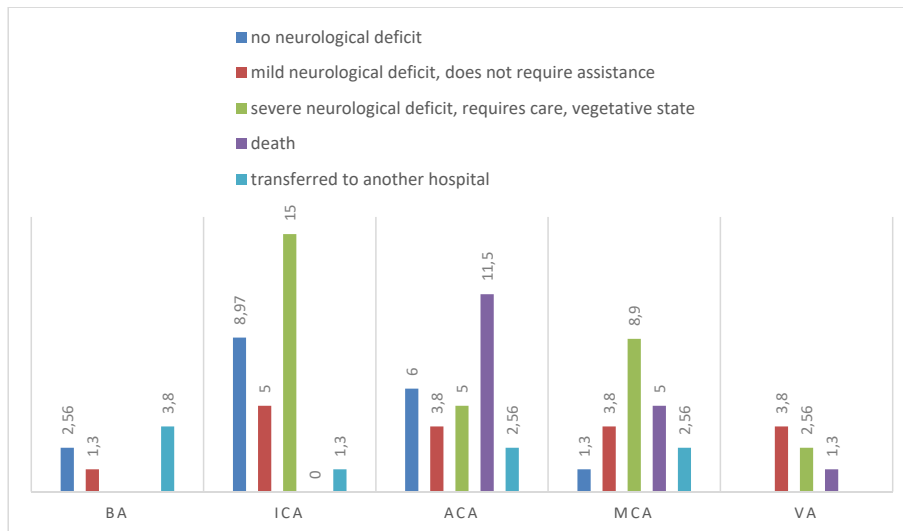


Fig. 4. Frequency distribution of treatment outcome depending on AA localization in Group 2 ($\chi^2=31.9$; $df=16$; $p<0.01$)

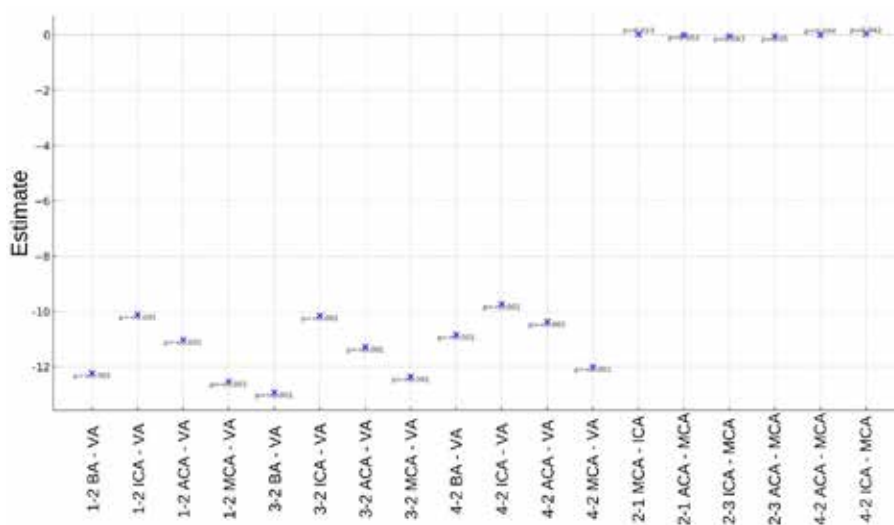


Fig. 5. Result of multinomial logistic regression in Group 1

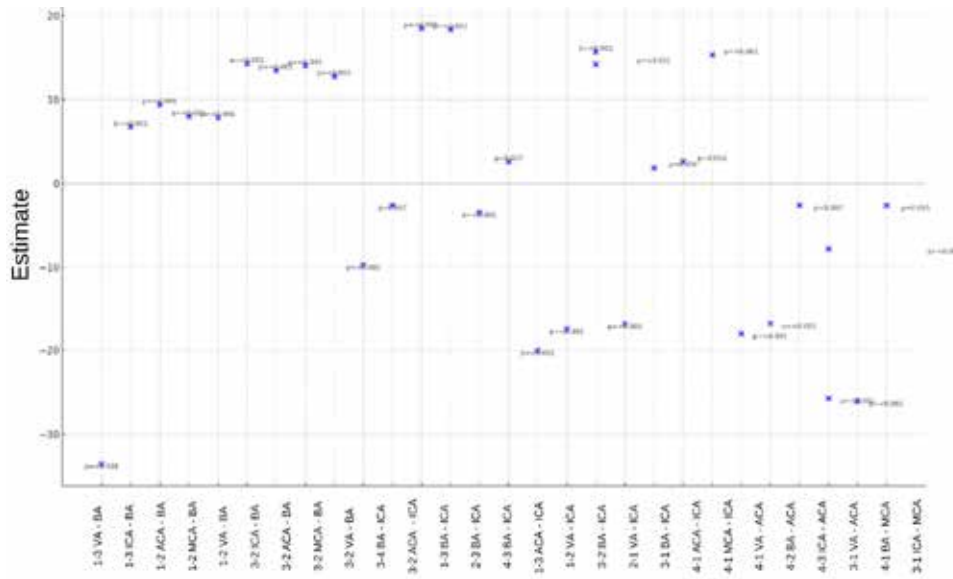


Fig. 6. Result of multinomial logistic regression in Group 2

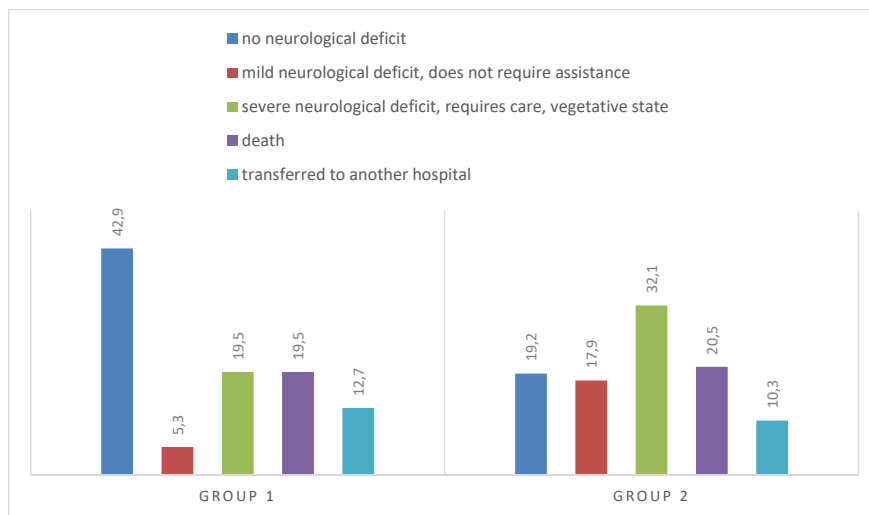


Fig. 7. Frequency distribution of treatment outcome depending on the presence of oculomotor disorders ($\chi^2=28.4$; $df=4$; $p<0.001$).

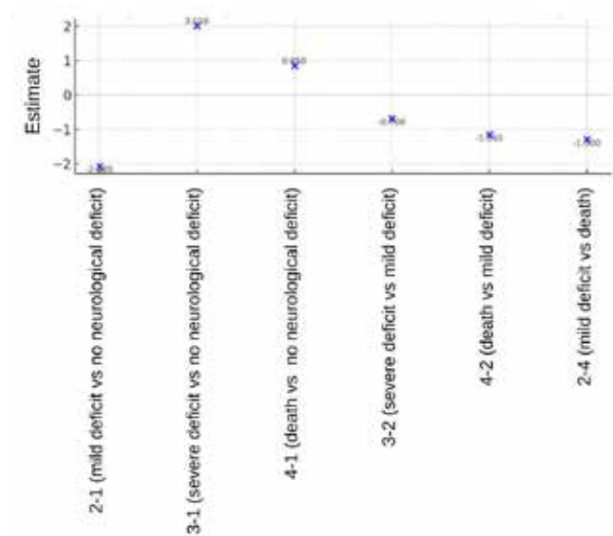


Fig. 8. Multinomial logistic regression results

The analysis of the dependency between treatment outcomes and the presence of OMDs demonstrated the following: the absence of OMDs increases the likelihood of discharge with mild neurological deficits and decreases the likelihood of discharge with severe neurological deficits compared to no deficit at all ($p < 0.001$) (Fig. 8).

Conclusions. The presence of oculomotor disorders in aneurysmal SAH increases the likelihood of a satisfactory treatment outcome, but reduces the likelihood of discharge without neurological deficit. The location of the ruptured aneurysm demonstrates a significant impact on the

likelihood of oculomotor disorders: with the localization of the ruptured AA in the ICA basin, patients have a 3.2-fold higher chance of developing oculomotor disorders compared to patients with aneurysms in the ACA area. The absence of oculomotor disorders in BA AA ruptures increases the likelihood of discharge with mild neurological deficit. The presence of oculomotor disorders in ICA AA ruptures increases the chances of discharge without neurological deficit, while MCA and ACA AA ruptures are associated with an increased risk of discharge with severe neurological deficit.

BIBLIOGRAPHY:

1. Finger G, Martins OG, Nesi WM et al. Ruptured aneurysm in the posterior communicating segment of carotid artery presenting with contralateral oculomotor nerve palsy. *Surg Neurol Int.* 2019;10:177. doi: 10.25259/SNI_203_2019.
2. Li Y, Zhao M, Li X, Liu T, Zheng L, Hu D, Liu T, Zhou L. Risk factors for recovery from oculomotor nerve palsy after aneurysm surgery: a meta-analysis. *PeerJ.* 2024;12:e18207. doi: 10.7717/peerj.18207.
3. Jan-Karl Burkhardt, Ethan A. Winkler, et al. Isolated abducens nerve palsy associated with subarachnoid hemorrhage: a localizing sign of ruptured posterior inferior cerebellar artery aneurysms. *J Neurosurg.* 2018;128(6):1830–1838 doi: 10.3171/2017.2.JNS162951.
4. Somagawa C, Fukuda Y, Yoshimura S et al. A Rare Case of Ruptured Internal Carotid-Posterior Communicating Artery Aneurysm Associated with Contralateral Delayed Oculomotor Nerve Palsy. *No Shinkei Geka.* 2017;45(7):629–635. [Japanese]. doi: 10.11477/mf.1436203562.
5. Srinivasan A, Dhandapani S, Kumar A. Pupil sparing oculomotor nerve paresis after anterior communicating artery aneurysm rupture: False localizing sign or acute microvascular ischemia? *Surg. Neurol Int.* 2015;6:46. doi: 10.4103/2152-7806.153877.
6. Bizilis JC, Simonin A, Lind CR. Delayed oculomotor nerve palsy associated with a ruptured anterior communicating aneurysm: Case report. *J Clin Neurosci.* 2021;90:56–59. doi: 10.1016/j.jocn.2021.04.018.
7. Gomez-Figueroa E, Cardenas-Saenz O, Quiñones-Pesqueira G et al. Bilateral Third Nerve Palsy in Mirror Aneurysms of the Posterior Communicating Arteries. *Eur J Case Rep Intern Med.* 2018;5(8):000912. doi: 10.12890/2018_000912.
8. Liu HJ, Lin Y, Feng YG. Predictors of Oculomotor Nerve Palsy with Posterior Communicating Aneurysm Clipping in a Surgically Treated Series of 585 Patients: A Single-Center Study. *World Neurosurg.* 2022;167:e117-e121. doi: 10.1016/j.wneu.2022.07.101.
9. Suda T, Matsushita E, Minamide H. Oculomotor nerve palsy owing to cerebral aneurysm. *QJM.* 2022;115(6):395–396. doi: 10.1093/qjmed/hcac097
10. Hou Yu, Chen R, Yang H, et al. Predictors of complete recovery of oculomotor nerve palsy induced by posterior communicating artery aneurysms in patients aged eighteen to sixty. *Journal of Clinical Neuroscience.* 2022;99: 212–216. doi: 10.1016/j.jocn.2022.03.015.
11. Nathal E, Yasui N, Suzuki A, Hadeishi H. Ruptured anterior communicating artery aneurysm causing bilateral abducens nerve paralyses--case report. *Neurol Med Chir (Tokyo).* 1992;32(1):17–20. doi: 10.2176/nmc.32.17.
12. Yaşargil, M. G. *Microneurosurgery, Vol. I: Microsurgical Anatomy of the Basal Cisterns and Vessels of the Brain* (Springer-Verlag).1984

Надійшла до редакції 17.10.2024 р.

Прийнята до друку 26.12.2024 р.

Електронна адреса для листування yuliia.solodovnikova@onmedu.edu.ua