

O. V. Denefil <https://orcid.org/0000-0002-3606-5215>
O. V. Sopol <https://orcid.org/0009-0000-4222-1424>
O. O. Levchuk <https://orcid.org/0000-0001-7241-3726>
O. M. Sopol <https://orcid.org/0000-0003-3807-1317>
O. P. Andriyishyn <https://orcid.org/0000-0001-7253-7761>

MORPHOLOGICAL CHANGES IN THE LIVER OF RATS OF BOTH SEXES WITH FRUCTOSE-INDUCED NONALCOHOLIC FATTY LIVER DISEASE

Ivan Horbachevsky Ternopil National Medical University of the Ministry of Health of Ukraine, Ternopil, Ukraine

UDC 616.36-091.8:616.36-003.826-02:547.455.633

O. V. Denefil, O. V. Sopol, O. O. Levchuk, O. M. Sopol, O. P. Andriyishyn
MORPHOLOGICAL CHANGES IN THE LIVER OF RATS OF BOTH SEXES WITH FRUCTOSE-INDUCED NONALCOHOLIC FATTY LIVER DISEASE

Ivan Horbachevsky Ternopil National Medical University of the Ministry of Health of Ukraine, Ternopil, Ukraine

The aim of study is to make a comparative analysis of structural changes in the liver rats of both sexes, which consumed 20% fructose solution instead of water for 2 months (after that they drank water for 2 months) and for 4 months.

Materials and methods: 72 white Wistar rats of both sexes were used in experiments. The age of the animals at the beginning of the research was 3.5–4 months. Rats were removed from of the experiment at the age of 7.5–8 months. The animals were divided into 3 groups: 1 – control, 2 – fructose-induced nonalcoholic fatty liver disease 2 months (after that they drank water for 2 months), 3 – fructose-induced nonalcoholic fatty liver disease 4 months. Fructose-induced nonalcoholic fatty liver disease in rats was induced by 20% fructose solution during 2 months (after that they drank water during 2 months) and 4 months. The development of nonalcoholic fatty liver disease was confirmed morphologically.

Results. Long-term use of a 20% fructose solution causes changes in lipid metabolism in the body of experimental animals, which is characterized by the development of fatty liver disease. Violation of the liver structure is more pronounced when consuming fructose for 4 months as compared to drinking fructose for 2 months with 2 months of rest. In female rats, compared to male ones, structural changes of the hepatic parenchyma (the volume of the affected areas and the degree of severity of changes in them) are significantly more evident in both terms of the study.

Key words: liver, nonalcoholic fatty liver disease, fructose, rats, sex, morphological changes.

УДК 616.36-091.8:616.36-003.826-02:547.455.633

О. В. Денефіль, О. В. Сопель, О. О. Левчук, О. М. Сопель, О. П. Андрійшин
МОРФОЛОГІЧНІ ЗМІНИ В ПЕЧІНЦІ РІЗНОСТАТЕВИХ ЩУРІВ У РАЗІ ФРУКТОЗНО-ІНДУКОВАНОЇ НЕАЛКОГОЛЬНОЇ ЖИРОВОЇ ХВОРОБИ ПЕЧІНКИ

Тернопільський національний медичний університет імені І. Я. Горбачевського Міністерства охорони здоров'я України, Тернопіль, Україна

В експериментах використано 72 різностатеві білі щури Вістар. Вік тварин становив 7,5–8 місяців. Неалкогольну жирову хворобу печінки викликали питтям 20% розчину фруктози протягом 2 (після цього 2 місяці пили воду) і протягом 4 місяців. Неалкогольна жирова хвороба печінки морфологічно підтверджена. Встановлено, що тривале, протягом 2 і 4 місяців, використання фруктози викликає зміни ліпідного обміну в організмі експериментальних тварин, що характеризуються розвитком жирової дистрофії печінки. Порушення структури печінки більш виражені у разі вживання фруктози протягом 4 місяців порівняно з 2 місяцями і 2 місяцями перерви. У самиць, порівняно із самцями, структурні зміни паренхіми печінки (об'єм уражених ділянок і ступінь вираженості змін) значно більші в обидва терміни дослідження.


Ключові слова: печінка, неалкогольна жирова хвороба печінки, фруктоза, щури, стать, морфологічні зміни.

Introduction. Dietary habits impact human health, which leads to the increase of obesity and associated diseases, such as non-alcoholic fatty liver disease (NAFLD), diabetes mellitus type 2, cardiovascular disease [1; 2]. Increased fructose intake is associated with obesity, metabolic syndrome and NAFLD [3; 4; 5]. High-fructose intake increases hepatic lipogenesis and content of liver fat, decreases sensitivity of hepatic cells to insulin independently from weight increase [6]. The consump-

tion of moderate amount of fructose containing sugar-sweetened fluid for a few weeks can induce insulin resistance and change the profile of serum fatty acids [7].

Hepatic fructose and glucose metabolism promote specific mechanisms of metabolic disturbances [8], because the liver plays an important role in fructose clearance. Regular consumption of fructose-sweetened beverages in moderate doses increases hepatic fatty acids synthesis even in a basal state [9], also fructose induces the main hepatic transcription factors that regulates the expression of lipogenic enzymes (fatty acid synthase and acetyl-CoA carboxylase) [10].

It is a compensatory mechanism, which enhances hexose disposal and supports metabolic homeostasis in



response to the uptake of carbohydrate loads [11], may increase lipogenesis from microbiota-derived acetate [12]. The amount and composition of carbohydrates in the diet can modify substrate flux in the liver.

A long (7 weeks) daily consumption of fructose, glucose and sucrose increased fasting human fibroblast growth factor 21 in healthy, thin men. Authors also concluded that excessive carbohydrates may impact human fibroblast growth factor 21 concentration in people suffering from the metabolic syndrome [13]. It can lead to liver fibrosis.

Non-alcoholic steatohepatitis is a progressive form of NAFLD associated with steatosis, hepatocellular injury, inflammation and fibrosis [14]. It is well known that a low free sugar diet in overweight/obese NAFLD patients may reduce hepatic steatosis and fibrosis. The mechanism is improving glycemic indices, decreasing the concentration of inflammation biomarkers, triglycerides, and level of total cholesterol [15].

The aim of the study is to make a comparative analysis of structural changes in the liver rats of both sexes, which consumed 20% fructose solution instead of water for 2 months (after that during 2 months they drunk water) and 4 months.

Research materials and methods. 72 white Wistar rats of both sexes were used in experiments. At the beginning of the research the age of the animals was 3.5–4 months. The rats were removed from the experiment at the age of 7.5–8 months. The animals were divided into 3 groups: 1 – control, 2 – nonalcoholic fatty liver disease induced with fructose consumption during 2 months (and after that they drunk water for 2 months), 3 – nonalcoholic fatty liver disease induced with fructose consumption during 4 months. Fructose-induced nonalcoholic fatty liver disease was induced by drinking 20% fructose solution instead of water during 2 months (and after that for 2 months they drank water) and 20% fructose solution during 4 months [16]. The development of fructose-induced nonalcoholic fatty liver disease was confirmed morphologically. Euthanasia of rats was carried out by total bleeding from the heart after previous thiopental-sodium anesthesia (60 mg/kg⁻¹ of the animal's body weight intraperitoneally). The pieces of liver were taken immediately after taken blood from the heart of the animal and fixed in a 10% solution of neutral formalin. No earlier than in two weeks, the preparations were washed in the tap water and held in alcohol, poured into paraffin blocks [17]. Morphological study of the liver was carried out in specimens stained with hematoxylin-eosin under a light microscope.

All experiments were carried out in the first half of the day at a temperature of 18–22°C, relative humidity of 40–60% and illumination of 250 lux. The experiments were performed in compliance with the norms of the Council of Europe Convention on the Protection of Vertebrate Animals Used for Research and Other Scientific Purposes (Strasbourg, March 18, 1986), the resolution of the First National Congress on Bioethics (Kyiv, 2001), and the order of the Ministry of Health of Ukraine No 690 of September 23, 2009.

Research results and discussion. No significant differences in the structure of the studied organ were found in light-microscopic specimens of the livers of the control group of rats of both sexes. The parenchyma of the liver looks quite

homogeneous, the hepatocytes in the hepatic lobules are located in the form of trabeculae (double chains of cells), which are oriented radially in relation to the central veins. There are no distinct layers of connective tissue between the lobules, so their boundaries are conditionally determined by the location of 6 hepatic triads on the periphery of each lobule. Blood filling of all vessels is moderate (Fig. 1).

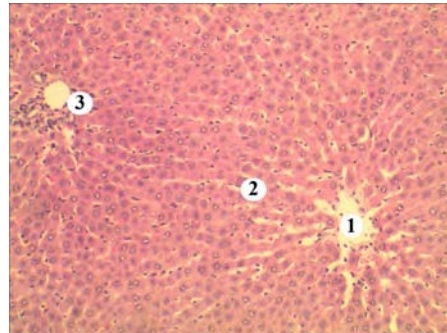


Fig. 1. A fragment of the liver of an intact female rat. Poorly defined lobular structure of the organ. 1. Central vein with blood formed elements. 2. Cords of hepatocytes. 3. Interlobular triad. Hematoxylin and eosin staining. x100

After 2 months of fructose drinking in the liver specimens, prominent parenchymal changes are revealed mostly at the periphery of female liver. They look like aggregations of enlarged hepatocytes with light oxyphilic inhomogeneous vacuolized cytoplasm. The cells were lying in a disorderly manner, their correct placement by beams, which are radially oriented in the liver lobules, was significantly disturbed, the nuclei of some cells were pycnotic. The orientation of hemocapillaries in the affected areas was disturbed, and outside the areas of fatty liver, their lumens were unevenly filled with blood (Fig. 2).

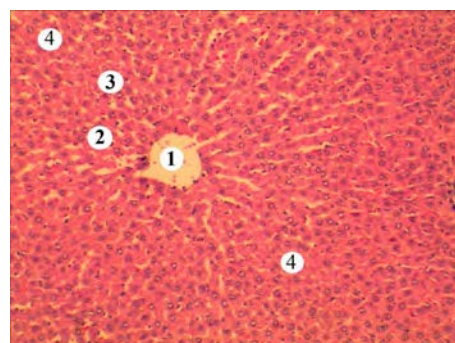


Fig. 2. 2 months of administration of 20% fructose solution, weakly expressed lobular structure of the female rat liver. 1. The central vein with blood formed elements. 2. Moderately changed cords of hepatocytes at the center of lobule. 3. Disorganized trabeculae of hepatocytes at the periphery. 4. Enlarged hepatocytes with vacuolized cytoplasm. Hematoxylin and eosin staining. x100

Hepatic parenchyma of male rats seems less changed at the same period of experiment. The areas of hepatocytes affected with lipid dystrophy were not so numerous and have smaller size. Cord-like arrangement of cells and hemocapillaries between them are better saved (Fig. 3).

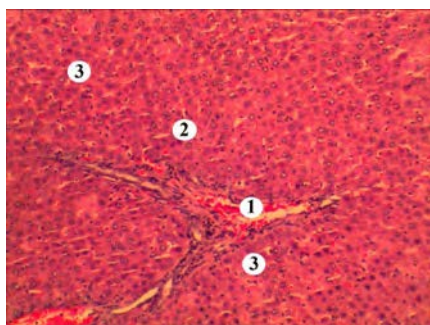


Fig. 3. A fragment of the male rat liver, 2 months of 20 % fructose solution drinking. Interlobular triad 1. Blood filled interlobular vein. 2. Clearly changed cords of hepatocytes. 3. Enlightenment and vacuolization of the cell cytoplasm. Hematoxylin and eosin staining. x100

At the same time, at the periphery of lobules, the signs of blood circulation disorders (dilatation and blood filling of vessels) are often revealed and in the nearest parenchyma the arrangement of cells was violated; the cytoplasm of enlarged cells is lighter and vacuolized. The irregular shaped heterochromatic nuclei in some hepatocytes looked pycnotic (Fig. 4).

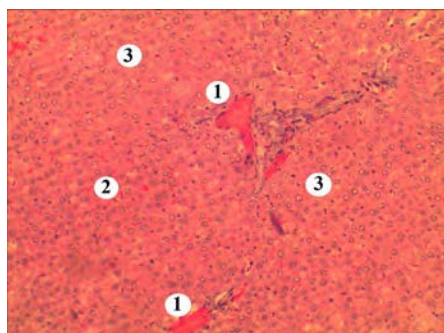


Fig. 4. A fragment of the female rat liver with triad, 2 months of 20 % fructose solution drinking. 1. Considerable hemostasis in veins. 2. Irregular arrangement of hepatocytes at the periphery of lobules. 3. Pronounced enlightenment of cells. Hematoxylin and eosin staining. x 100

Excessive fructose consumption causes the development of NAFLD, but data of literature [18] show that limitation of fructose consumption for six weeks led to a small, but statistically significant, decrease in intrahepatic lipid content in comparison with the isocaloric control group. In our experiment, greater changes were found in a female rat liver.

According to the literature data, there are the similar results in humans [19]. High fructose food significantly increased postprandial hepatic lipogenesis *de novo* and this effect was evident in women. Despite an increase in hepatic lipogenesis *de novo*, there was no change in dietary fatty acid oxidation. Women are more responsive to higher amounts of fructose in food than men. Long-term keeping to that bad habit may lead to changes in hepatic fatty acid distribution and eventually liver fat [19]. That we observed in the next part of the experiment, where fructose intake continued for 4 months.

The common structure of the liver is significantly changed. Numerous large areas of dystrophically altered cells are revealed, which (places) differ in color heterogeneity, have different sizes and are present now both at the periphery and centrally in lobules. The cells in them are significantly larger and their cytoplasm is lightened, and nuclei are weakly contoured. In cells of larger nodules, the nuclei are practically indistinguishable. Among the hepatocytes outside the changed areas, a greater number of dark cells had heterochromatic nuclei (Fig. 5).

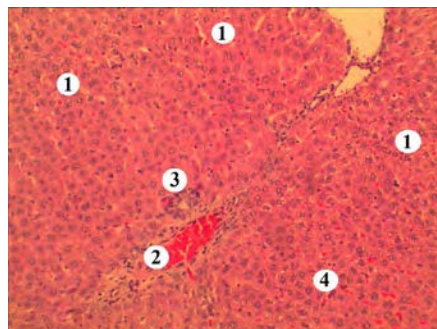


Fig. 5. A fragment of the liver of a female rat after 4 months of 20 % fructose solution drinking. 1. Numerous changed hepatocytes with inhomogeneous cytoplasm. 2. A dilated vein with significant blood filling. 3. Bile duct. 4. Cells with heterochromatic nuclei. Hematoxylin and eosin staining. x 100

Under high magnification, a pronounced dilatation and blood filling of the organ's vessels is revealed, the hepatic cords don't have a clear radial arrangement in the lobules, in some noduli, hepatocytes are completely destroyed and replaced by a homogeneous slight oxyphilic mass (lipids). Lymphohistiocytic infiltrates are found around the vessels in the hepatic triads. In the hepatic parenchyma outside the pathological nodes, the cytoplasm of most cells looks heterogeneously vacuolated, the size of such vacuoles ranging from small to medium. Single cells with signs of mitotic division are found between such vacuolated hepatocytes (Fig. 6).

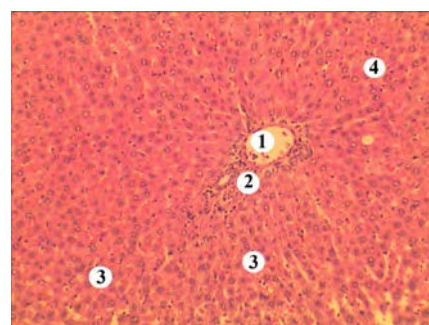


Fig. 6. A fragment of the liver of a male rat after 4 months of 20 % fructose solution drinking. 1. Interlobular vein lumen. 2. Aggregation of lymphocytes and histiocytes in hepatic triad. 3. Vacuolized hepatocytes. 4. Mitotic figures. Hematoxylin and eosin staining. x 100

In the histological specimens of the liver of male rats, a smaller number of steatohepatosis nodules is revealed. Like

in the female rats' liver they are located diffusely in different parts of the organ, but their sizes are comparatively smaller than in females. The general cytoarchitectonics of the liver is also significantly disturbed – the lobular structure is not pronounced, but the radial arrangement of the hepatic cords around the central veins is preserved better than in females (Fig. 7). Similar to the female liver, the majority of hepatocytes outside the damaged areas of pronounced fatty degeneration contain numerous small and medium-sized vacuoles, which makes their cytoplasm heterogeneous (Fig. 8).

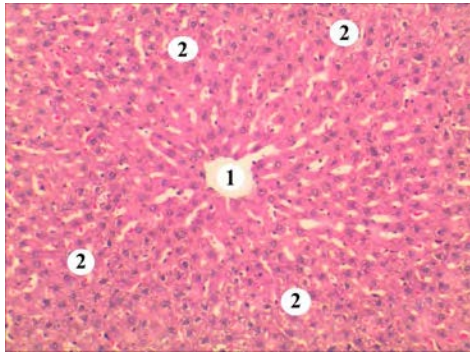


Fig. 7. A fragment of the liver of a female rat after 4 months of 20% fructose solution drinking. 1. Areas of steatohepatosis. 2. Lumen of the central vein. Hematoxylin and eosin staining. x 100

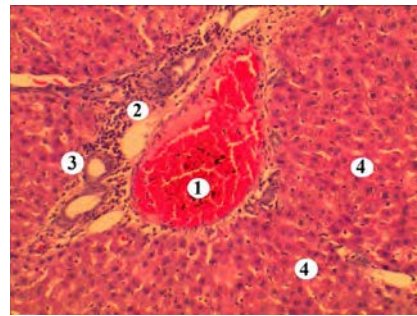


Fig. 8. A fragment of the liver of a male rat after 4 months of 20% fructose solution drinking. 1. Formation of a blood clot. 2. Aggregations of lymphocytes and histiocytes. 3. The bile duct. 4. Hepatocytes with a vacuolized cytoplasm. Hematoxylin and eosin staining. x 100

Significant blood filling of vessels and accumulation of lymphocytes and histiocytes around them is also observed. Dividing hepatocytes are found a little more often than in the preparations of female rats, but dark hepatocytes were revealed less frequently. Under high magnification, heterogeneity of hepatocyte cytoplasm is clearly visible.

Conclusions. A long usage of a 20% fructose solution causes changes in lipid metabolism in the body of experimental animals, which is characterized by the development of fatty liver disease. Disturbance of the liver structure is more pronounced when consuming fructose for 4 months compared to 2 months with 2 months of rest. In female rats, compared to male, parenchymal changes of the liver (the volume of the affected areas and severity of changes) are significantly more evident in both terms of the study.

Conflict interests. The authors declare no conflict of interest.

BIBLIOGRAPHY

- Kim D, Konyon P, Cholankeril G, Ahmed A. Physical activity is associated with nonalcoholic fatty liver disease and significant fibrosis measured by fibroscan. *Clin. Gastroenterol. Hepatol.* 2022; 20(6): 143855. doi: 10.1016/j.cgh.2021.06.029.
- Anstee QM, Mantovani A, Tilg H, Targher G. Risk of cardiomyopathy and cardiac arrhythmias in patients with nonalcoholic fatty liver disease. *Nat. Rev. Gastroenterol. Hepatol.* 2018; 15(7): 425–439. doi: 10.1038/s41575-018-0010-0.
- Cong F, Zhu L, Deng L, Xue Q, Wang J. Correlation between nonalcoholic fatty liver disease and left ventricular diastolic dysfunction in non-obese adults: a cross-sectional study. *BMC Gastroenterol.* 2023; 23(1): 90. doi: 10.1186/s12876-023-02708-4.
- El Hadi H, Di Vincenzo A, Vettor R, Rossato M. Relationship between heart disease and liver disease: A two-way street. *Cells.* 2020; 9(3)567. doi: 10.3390/cells9030567.
- Scalzo N, Canastar M, Lebovics E. Part 1: Disease of the Heart and Liver: A Relationship That Cuts Both Ways. *Cardiol Rev.* 2022; 30(3): 111–122. doi: 10.1097/CRD.0000000000000379.
- Anstee QM, Day CP. The Genetics of Nonalcoholic Fatty Liver Disease: Spotlight on PNPLA3 and TM6SF2. *Semin Liver Dis.* 2015; 35(3): 270–290. doi: 10.1055/s-0035-1562947.
- Targher G, Corey KE, Byrne CDJD. Metabolism. NAFLD, and cardiovascular and cardiac diseases: Factors influencing risk, prediction, and treatment. *Diabetes Metabolsm.* 2021; 47(2): 101215. doi: 10.1016/j.diabet.2020.101215.
- Targher G, Valbusa F, Bonapace S, et al. Non-alcoholic fatty liver disease is associated with an increased incidence of atrial fibrillation in patients with type 2 diabetes. *PLoS ONE.* 2013; 8(2): 57183. doi: 10.1371/journal.pone.0057183.
- Geidl-Flueck B, Hochuli M, Németh Á et al. Fructose- and sucrose- but not glucose-sweetened beverages promote hepatic de novo lipogenesis: A randomized controlled trial. *J. Hepatol.* 2021; 75(1): 46–54. doi: 10.1016/j.jhep.2021.02.027.
- Williams FR, Williams FR, Vallance A et al. Home-based exercise in patients awaiting liver transplantation: a feasibility study. *Liver Transpl.* 2019; 25(7): 995–1006. doi: 10.1002/lt.25442.
- Turri-Silva N, Ricci-Vitor AL, Cipriano GJr et al. Functional resistance training superiority over conventional training in metabolic syndrome: A randomized clinical trial. *Res. Q. Exerc. Sport.* 2020; 91(3): 415–424. doi: 10.1080/02701367.2019.1679333.
- He B, Lu Z, He W, Huang B, Jiang H. Autonomic modulation by electrical stimulation of the parasympathetic nervous system: An emerging intervention for cardiovascular diseases. *Cardiovasc. Ther.* 2016; 34(3): 167–171. doi: 10.1111/1755-5922.12179.

13. Geidl-Flueck B, Hochuli M, Spinass GA, Gerber PA. Do Sugar-Sweetened Beverages Increase Fasting FGF21 Irrespective of the Type of Added Sugar? A Secondary Exploratory Analysis of a Randomized Controlled Trial. *Nutrients*. 2022; 14(19): 4169. doi: 10.3390/nu14194169.
14. Harrison SA, Ratziu V, Anstee QM et al. Design of the phase 3 MAESTRO clinical program to evaluate resmetirom for the treatment of nonalcoholic steatohepatitis. *Aliment Pharmacol Ther*. 2024; 59(1): 51–63. doi: 10.1111/apt.17734.
15. Khodami B, Hatami B, Yari Z et al. Effects of a low free sugar diet on the management of nonalcoholic fatty liver disease: a randomized clinical trial. *Eur J Clin Nutr*. 2022; 76(7): 987–994. doi: 10.1038/s41430-022-01081-x.
16. Kostiuk OA, Denefil OV, Holovata TK. Changes in biochemical parameters in the blood of high- and low-emotional rats with ethanol hepatitis. *Medical and clinical chemistry*. 2018; 20(3): 125–132. doi.org/10.11603/mcch.2410-681X.2018.v0.i3.9578 (in Ukrainian).
17. Horalskyi LP, Khomych VT, Kononskyi OI. Fundamentals of histological technique and morphofunctional research methods in normal and pathology: textbook. Zhytomyr: ZhNAEU, 2019: 286 p. (in Ukrainian).
18. Simons N, Veeraiyah P, Simons PIHG et al. Effects of fructose restriction on liver steatosis (FRUITLESS); a double-blind randomized controlled trial. *Am J Clin Nutr*. 2021; 113(2): 391–400. doi: 10.1093/ajcn/nqaa332.
19. Low WS, Cornfield T, Charlton CA, Tomlinson JW, Hodson L. Sex Differences in Hepatic De Novo Lipogenesis with Acute Fructose Feeding. *Nutrients*. 2018; 10(9): 1263. doi: 10.3390/nu10091263.

Надійшла до редакції 15.03.2024 р.

Прийнята до друку 30.05.2024 р.

Електронна адреса для листування denefil@tdmi.edu.ua